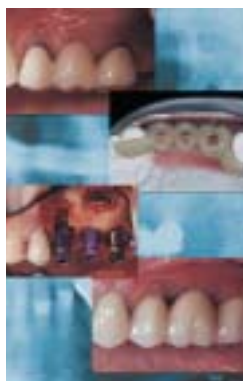

# Immediate Implant Placement and Provisionalization in Edentulous, Extraction, and Sinus Grafted Sites

## CE 1

Paul S. Petrunaro, DDS, MS  
Private Practice  
Stillwater, Minnesota

**Abstract:** *The incorporation of restorative procedures during implant placement, as well as during the creation of natural emergence profiles and lifelike ceramic restorations, has become the focus of implantology over the last few years. Recent publications have provided guidelines for success with the immediate restoration procedure and have presented basic surgical protocols for the implant team. Enhancement of the healing phase through the local delivery of growth factors to the surgical site, as well as through advancements in bone grafting materials, has allowed the implant surgeon to accomplish multiple surgical procedures during the initial surgical visit. In addition, advancements in surgical stent designs have allowed the restorative dentist to adequately communicate to the surgeon during surgery the parameters required in the final restoration to replace the natural tooth system with form, function, and esthetics. This article presents the results of more than 400 immediate restored implants placed in edentulous sites, fresh extraction sockets, and sinus grafted sites. Also highlighted are guidelines for surgical success, as well as a description of a surgical stent design that communicates requirements for restorative success to the surgeon, while also serving as an esthetic provisional restoration.*



Because of its high success rates, implant therapy is being included in treatment plans more routinely. It is now possible to achieve esthetics with single tooth implant restorations, allowing the implant team to offer patients predictable, lifelike restorations that are biologically sound. Additionally, advancements in surgical procedures are allowing implant surgeons to provide the restorative doctor with a fixed nonloaded restoration during surgery. More recently, Wohrle,<sup>1</sup> Salama and colleagues,<sup>2</sup> and Saadoun and Le Gall<sup>3</sup> have presented guidelines for surgical protocols

that allow the implant team to present predictable and esthetic transitionals during surgery. This leads to esthetic implant restorations.

Several authors<sup>4-8</sup> have documented the importance of the dento-implant-gingival complex, explaining how parameters for success in natural tooth restorations, regarding soft tissue emergence profiles, papillary contours, and a healthy biologic width, can be extrapolated to implant restorations placed within the natural tooth-tooth space (ie, single tooth replacement), or implant-implant space (ie, multiple adjacent implant sites). Most recently, Kan and

### Learning Objectives:

After reading this article, the reader should be able to:

- discuss guidelines for surgical success with immediate implant placement and restoration of dental implants in single and multiple sites.
- list advancements in surgical techniques that allow the implant surgeon to reduce treatment times and possible surgical visits.
- describe a surgical guide/provisional restoration system.

**Table 1—Immediate Restoration Procedure (all sites)**

Immediate Extraction/ Implant Placement	209
Edentulous Ridges	166
Sinus Elevation	77
PRP*	427
Implant Surface Enhancement HA/RBM†	452
Total Implants Placed	452
Nonintegrated at Load	10
Initial Rate of Success	97.8%

\*PRP-Platelet Rich Plasma.  
†HA-Hydroxylapatite, RBM-Resorbable Blast Media.

**Table 2—Immediate Restoration Procedure: Edentulous Ridge**

Edentulous Ridges	166
PRP*	166
Implant Surface Enhancement HA/RBM†	166
Total Implants Placed	166
Nonintegrated at Load	3
Initial Rate of Success	98.1%

\*PRP-Platelet Rich Plasma.  
†HA-Hydroxylapatite, RBM-Resorbable Blast Media.

Rungcharassaeng<sup>8</sup> and Saadoun<sup>9</sup> have presented surgical rationales for immediate placement and provisionalization of anterior single implants. These protocols advocate an approach that either does not require an incision, or that requires one that is conservative and papillary-sparing. Recent advancements in the enhancement of the healing phase, by the localized delivery of growth factors to the surgical

site,<sup>10,11</sup> have allowed surgeons to better control the soft tissues and to achieve full-thickness flap elevation. This incision approach allows the surgeon to evaluate, before implant placement, the integrity, or lack thereof, of the buccal plate, interdental bone heights, condition of the extraction socket, edentulous ridge width, height, and contours.<sup>12,13</sup>

This article reviews a new surgical approach to the immediate placement and restoration of dental implants in single and multiple sites. The protocol is applicable to edentulous sites, fresh extraction sockets, and sinus grafted sites. Tables 1 through 4 present results of more than 400 implants. The article also describes a surgical guide/provisional restoration system that allows the convenient transfer of the surgical guide to the esthetic provisional restoration during surgery, and allows the restorative dentist and laboratory technician to adequately translate the required information for correct implant placement. This initiates the foundation necessary for proper restorative completion.

## Guidelines for Determining When to Perform Immediate Implant Placement and Restoration Procedures

### Indications

- anterior sites
- single/multiple, maxillary/mandibular, posterior site
- single/multiple, maxillary/mandibular, edentulous ridges, immediate extraction sockets, pneumatized sinus regions, fractured/failed endodontically treated sites, periodontally affected sites (chronic, nonactive)

### Contraindications

- periodontally infected sites (active)
- sinus pathology, ridge defect where initial stabilization of the implant cannot be achieved
- full arch immediate restorations (where one stable occlusal stop does not exist)

## Pretreatment Planning

The surgeon should conduct a complete medical and dental evaluation before performing the implant restoration. Maxillary and mandibular study models should be obtained and mounted on an articulator. Evaluation of the surgical site involves referral to the dental laboratory for a diagnostic wax-up of the hard

**Table 3—Immediate Restoration Procedure: Sinus Elevation**

Sinus Elevation	77
PRP*	77
Implant Surface Enhancement HA/RBM†	77
Total Implants Placed	77
Nonintegrated at Load	1
Initial Rate of Success	98.7%

\*PRP-Platelet Rich Plasma.  
†HA-Hydroxylapatite, RBM-Resorbable Blast Media.

**Table 4—Immediate Restoration Procedure: Immediate Extraction/Immediate Extraction**

Immediate Extraction/ Implant Placement	209
PRP*	209
Implant Surface Enhancement HA/RBM†	209
Total Implants Placed	209
Nonintegrated at Load	6
Initial Rate of Success	97.1%

\*PRP-Platelet Rich Plasma.  
†HA-Hydroxylapatite, RBM-Resorbable Blast Media.

and soft tissues that need to be replaced.<sup>14</sup> After the diagnostic wax-up has been evaluated (Figure 1), the laboratory converts it to a surgical guide/temporary restoration (Figure 2). The TempStent™ method, which the author developed,<sup>15</sup> allows the restorative dentist to communicate to the surgeon the parameters necessary for a successful, and biologically sound, implant restoration. It also enables the surgeon to predetermine the angulation and spatial position of the implant (Figure 3), as well to visualize the position of the implant collar and its relationship to the sulcular portion of the planned restoration and interdental/interimplant bone contours. Additionally, the stock abutment can be prepared and the temporary approximated before the initial surgical visit (Figure 4).

**Surgical Technique**

*Preoperative Antibiotic Administration*

Administration of Augmentin®,<sup>a</sup> 875 mg is recommended. Dosage: 2 tablets every 12 hours the day before surgery; 1 tablet the day of surgery (before the surgical visit), followed by another tablet 12 hours later. Completion of the prescription for 8 days (2 tablets daily every 12 hours) provides adequate coverage. For patients sensitive to penicillin, Zithromax®,<sup>b</sup> (azithromycin) 250 mg is appropriate. Dosage: 2 tablets the

day before surgery; 1 tablet the day of surgery, followed by 1 tablet each day for 3 days after the surgical procedure.

*Atraumatic Tooth Removal, Sinus Elevation, or Edentulous Site Preparation*

An atraumatic surgical approach is necessary, in conjunction with sinus elevation, as it is with any immediate implant placement. The surgeon must take great care to maintain the buccal plate and existing interdental bone. In sinus elevation cases, whether using the lateral wall osteotomy approach, or the osteotome technique, the surgeon must also be sure to preserve the Schneiderian membrane. Efficient site preparation should preserve the integrity of the edentulous ridge, extraction socket, and sinus cavity/posterior maxillary ridge.

*Debridement of Existing Periodontal/Periapical Infection and/or Periodontal Ligament*

It is absolutely essential to remove any granulomatous tissue, in addition to periodontal ligament fibers, that may be present in the surrounding alveolar bone. This provides the existence of a bone/implant interface.

**Implant Selection and Implant Placement**

The implant of choice for this technique should be one with a thread design that is self-tapping in nature. The implant should be

<sup>a</sup>GlaxoSmithKline, Philadelphia, PA 19102; (800) 825-5249

<sup>b</sup>Pfizer, Inc, New York, NY 10017; (212) 733-2323

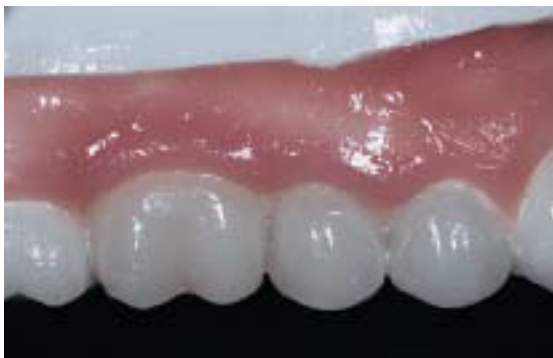

Figure 1—Diagnostic wax-up.

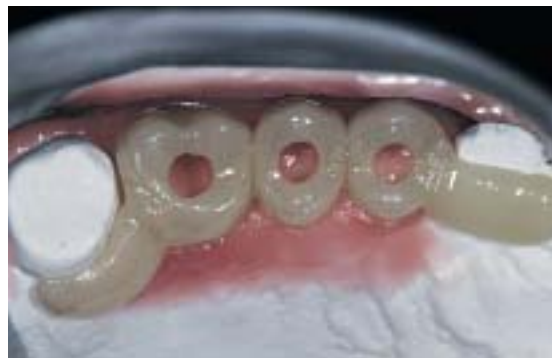

Figure 2—TempStent™ surgical stent/provisionalization system.

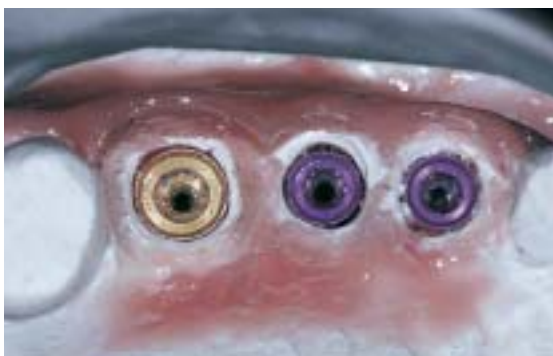

Figure 3—Analogues set into maxillary study cast.

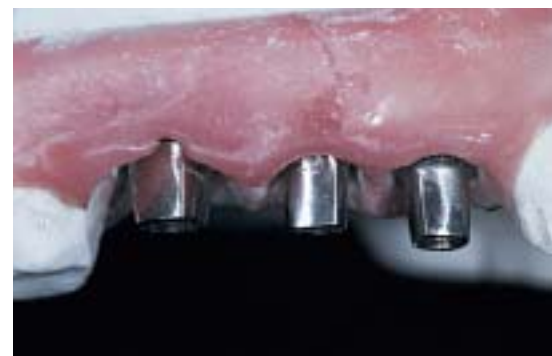

Figure 4—Preparation of stock abutments on the TempStent™ model.

tapered, which provides the best chance for obliterations of the coronal portion of the socket. It also mimics the natural convergence, which occurs in the natural tooth system, to the apical portion of the socket. The implant surface should be roughened with surface enhancements to promote a rapid integration and to enhance the initial stabilization of the fixture. The polished implant collar should be  $\leq 1$  mm in height, which allows the final position of the implant collar to be at a position that is superior to the crest of the bone. This position allows soft tissue attachment in the region of the collar. The roughened implant surface at the first thread, or at its smooth transfer from the polished collar to the roughened surface, allows bone attachment. Placing the implant in this fashion eliminates the “dieback” phenomenon.

### Grafting Material

According to the author’s clinical experience, autogenous bone is the best grafting material available. It is osteoconductive, osteoinductive, and osteogenic.<sup>16-19</sup> However, one of the drawbacks of autogenous bone is that a second surgical site is necessary to harvest the bone tissue. Many of these techniques require compli-

cated surgical procurement and add significant surgical time and morbidity. Other options include the use of allogenic, alloplastic, and xenographic<sup>20,21</sup> grafting materials, either with or without the use of various regenerative barriers. All have been well documented.<sup>22</sup> The nonautogenous grafting material should be biocompatible with the host tissue, osteoconductive,<sup>23-27</sup> osteoinductive,<sup>28,29</sup> and osteotrophic.<sup>30,31</sup> Not all allogenic or alloplastic grafting materials possess these important qualities. Some must rely on a vehicle to reconstitute their granular form. The author<sup>32-34</sup> and others<sup>35,36</sup> have observed that platelet-rich plasma (PRP) has enhanced the osteoconductive, and possibly the osteoinductive, properties of various allogenic, alloplastic, and xenographic materials.

### Platelet-Rich Plasma

The ideal autogenous vehicle for reconstituting the alloplastic, allogenic, or xenographic substrate is PRP (autologous platelet gel),<sup>37,38</sup> which is developed from autologous blood with a cell separator. The cell separator used herein follows a dual spin cycle and is complete in 12 minutes (Smart PreP™,c). Centrifugation of 55 mL of whole blood results in 10 mL of PRP

<sup>c</sup>Harvest Technologies Corporation, Plymouth, MA 02360; (508) 732-7500

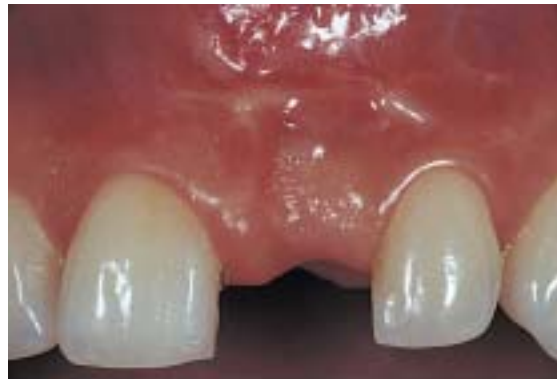**Table 5—Substances Released by Degranulation of Platelets**

Platelet-derived growth factor	(PDGF)
Transforming growth factor-beta	(TGF- $\beta$ )
Platelet-derived endothelial cell growth factor	(PD-ECCF)
Insulin-like growth factor	(IGF)
Vascular endothelial cell growth factor	(VEGF)

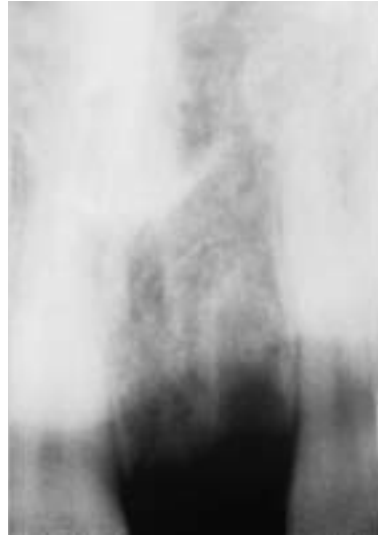
which, when simultaneously mixed with thrombin and calcium chloride, results in the degranulation of the platelets and subsequent release of growth factors. This stimulates both hard and soft tissue maturation and promotes healing. For this reason, PRP is the ideal vehicle for reconstituting the substrate because it enhances the osteoconductive qualities and, perhaps, osteoinductive properties of the allogenic, alloplastic, or xenographic graft materials. In addition, some have observed that PRP accelerates soft tissue maturation, which allows the gingival tissues to rapidly heal with minimal postsurgical contour alterations. Table 5 lists substances released by the degranulated platelets.

### Abutment Selection

Abutment selection is achieved by using the carrier mechanism of the implant system (a temporary abutment) or a stock abutment (which the restorative dentist could use as a final abutment). Both of these require preparation. The incorporation of the temporary/surgical guide system, which the author uses, allows advance preparation of the stock abutment in the dental laboratory. This eliminates the repeated removal of carrier mechanisms, intraoral preparation of the abutment (which produces heat and micro-movement via vibration), and impression copings for implant indexing at the time of placement. It is important to remember that many times, with immediate tooth removal/immediate implant placement (especially in sinus elevations), the quality of bone is compromised. Whatever the surgeon can do to minimize external forces to the fixture is beneficial. A stock-angled abutment that is easily prepared



**Figure 5A**—Pretreatment view of edentulous site at tooth No. 8.



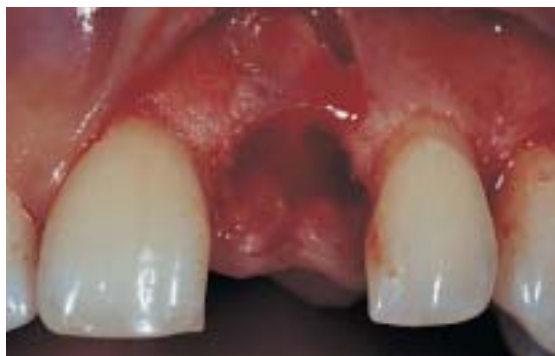**Figure 5B**—Preoperative periapical radiograph.

suffices when the stock abutment provided does not allow an appropriate path of insertion for the restoration because of the angle of implant placement.

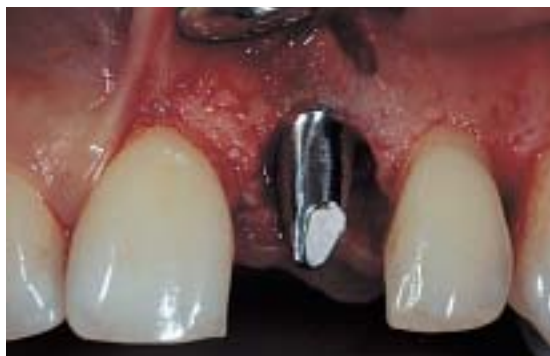### Temporary Restorative Material/Temporary Construction

The next step is the ideal temporary construction method, as discussed previously. The TempStent™ method allows the efficient transfer of a surgical guide into an esthetic provisional restoration that closely mimics that of the planned final restoration, in regard to emergence profile formation, interdental contours, contact points, and gingival contour at the facial marginal aspect. After completion of the temporary, the clinician must carefully evaluate the patient's occlusion. The provisional should not have occlusal contact in the centric relation position, or lateral excursive or protrusive contacts. After 3 months (4 or 5 months in sinus grafted cases) the prosthodontist or reconstructive dentist can fabricate the final implant-supported restoration. The temporary

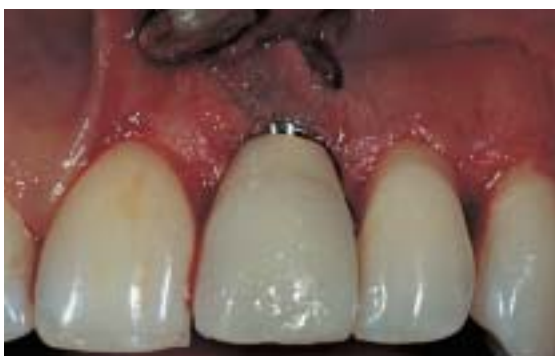



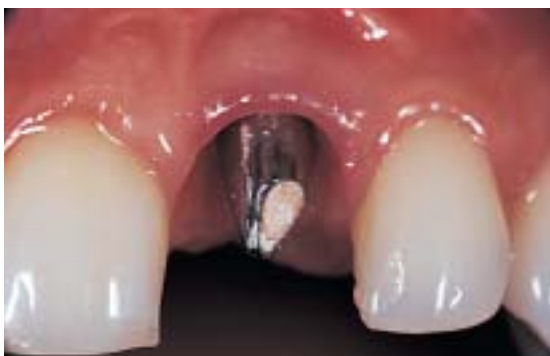**Figure 5C**—Creation of the sculpted implant receptacle site with PRP inserted into the osteotomy site.



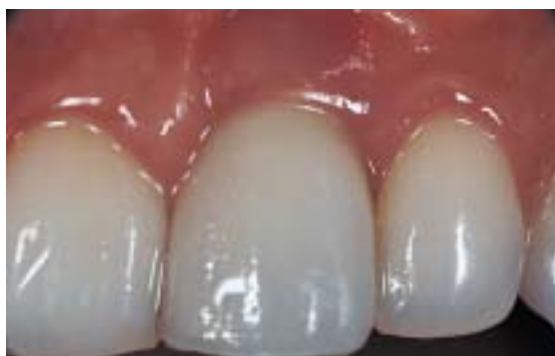**Figure 5D**—Prepared, polished stock abutment seated.



**Figure 5E**—Provisional restoration cemented.



**Figure 5F**—Emergence profile formation at 3 months postoperatively.



**Figure 5G**—Final implant-supported restoration.

restoration can be cemented with a temporary cement, and once again, confirmation of non-load can be obtained.

### Suture Material

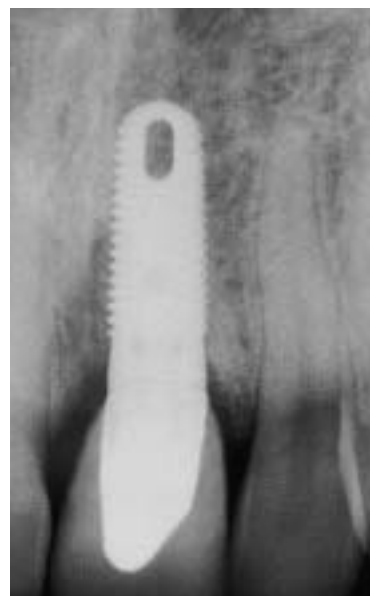A 5.0 monofilament (Monocryl<sup>d</sup>), or 4.0 Vicryl Rapide suture is recommended. The suture is small enough in diameter and resorbs over 30 to 45 days (Vicryl Rapide in 10 to 14 days), allowing proper stabilization and maturation of the soft tissues.

### Postoperative Course

As stated earlier, the prescribed healing phase is 3 months in immediate extraction or

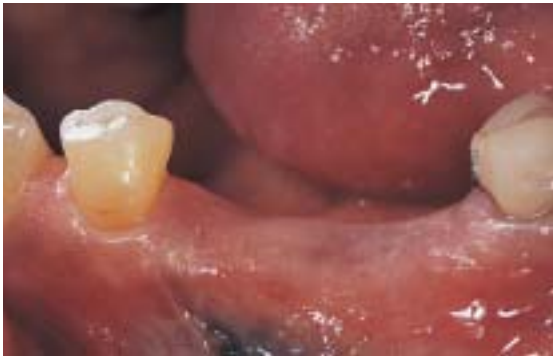<sup>d</sup>Ethicon, Inc, Somerville, NJ 08876; (800) 255-2500

**Figure 5H**—Case complete peri-apical radiograph.

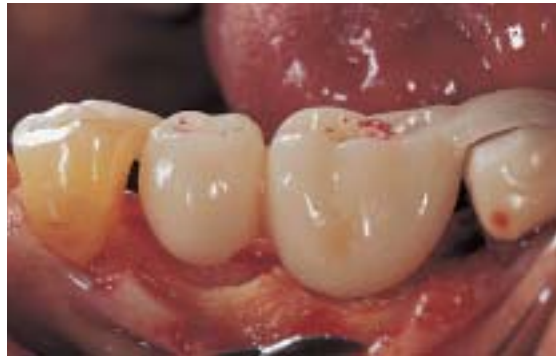

edentulous ridge cases, and 4 to 5 months in sinus grafted cases. After 3 to 5 months, if the restorative clinician uses the stock abutment seated at the initial visit, the abutment is torqued to 30 Ncm, and the temporary is re-cemented. Routine restorative procedures are followed from that point.

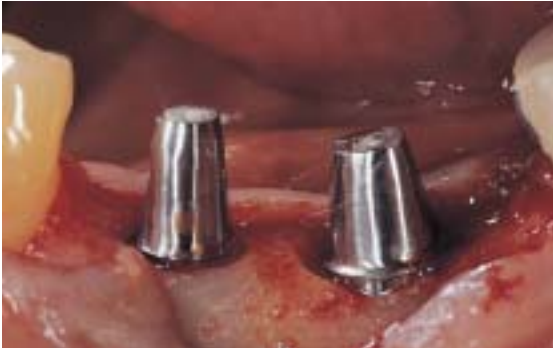If the restorative dentist requests a custom abutment, the patient is referred back to the restorative clinician for routine impression



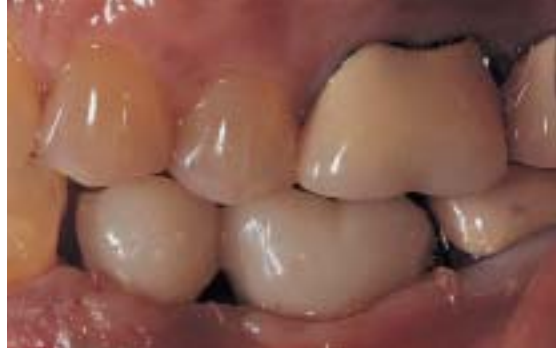**Figure 6A**—Preoperative view of the mandibular left posterior sextant at teeth Nos. 19 and 20.



**Figure 6B**—TempStent™ seated clinically after creation of the sculpted implant receptacle site.



**Figure 6C**—Seating the prepared, polished stock abutments.



**Figure 6D**—Closure and the left lateral clinical view.

techniques at fixture level with a transfer coping. When fabrication of the custom abutment is completed, the abutment is seated and torqued at 30 Ncm, and completion of the implant supported restoration proceeds as normal.

The case reports that follow describe the immediate implant placement and provisionalization procedure outlined in an edentulous site, an immediate extraction site, and a sinus grafted site.

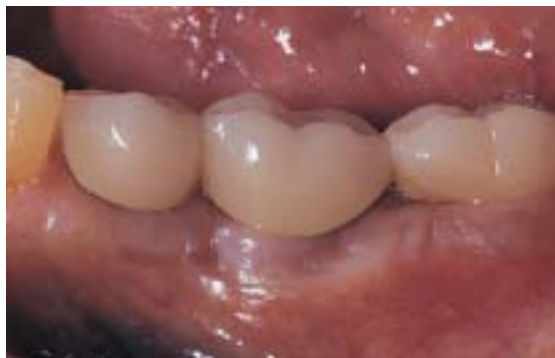### Case 1—Single Tooth Implant

A 33-year-old woman (nonsmoker) presented for implant reconstruction at the edentulous site at tooth No. 8 (Figure 5A). The preoperative periapical radiograph is shown in Figure 5B. After completing a diagnostic waxing of both the hard and soft tissues that need to be replaced, the clinician can evaluate the necessary regeneration procedures that need to be performed, in conjunction with implant placement; ascertain the width and length of the planned final restoration; plan soft tissue contours; and fabricate a surgical stent/provisional restoration (TempStent™).

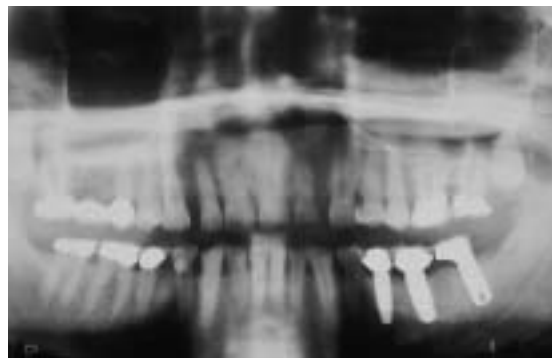
After administering an appropriate local anesthetic and full-thickness flap elevation, the clinician prepares a sculpted implant

receptacle site in the alveolar crest (Figure 5C) by mimicking the flow of the facial bone margins from tooth No. 8 to tooth No. 10. This sculpted implant receptacle site also allows the creation of interdental bone contours (Figure 5C) and osseous foundation, which sculpts the emergence profile of the final restoration. After atraumatic site preparation, the clinician applies PRP to the osteotomy site (Figure 5C) and coats the implant surface with PRP before placement. A 4.7-mm Tapered Screw Vent<sup>®</sup>, HA-coated, 13-mm length implant is placed in the osteotomy site. After implant placement and removal of the implant carrier, an HLA 4/5 stock abutment<sup>®</sup> is prepared and polished extraorally, and securely seated in the implant (Figure 5D).

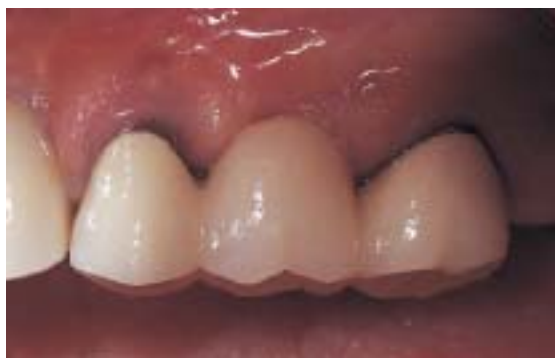Retrofitting of the TempStent™ surgical guide/provisional restoration completes the transitional restoration, while marginal adaptation is completed with the abutment that has been prepared extraorally. After the abutment/provisional margins have been adapted, the entire abutment/temporary restoration complex is reinserted and cemented, respectively, at the implant site (Figure 5E). Cementation is completed with a strong temporary cement. Veneering of the buccal plate



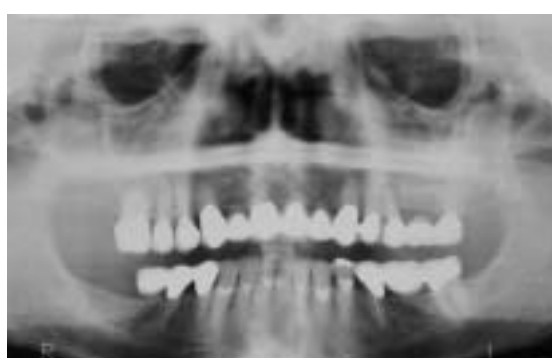**Figure 6E**—Case complete clinical appearance of three immediate restored implants at 4 months after surgery.



**Figure 6F**—Case complete panoramic radiograph.



**Figure 7A**—Preoperative clinical view, maxillary left posterior sextant.



**Figure 7B**—Preoperative panoramic view, maxillary left posterior sextant.

and correction of the fenestration at the facial of tooth No. 9, with a PRP/PepGen P-15™ graft complex<sup>f</sup>, provide the foundation for regeneration of the insufficient alveolar buccal crest. Creation of a bioactive membrane by application of PRP, followed by platelet-poor plasma (PPP) over the entire graft complex and surgical site, aids in the local delivery of growth factors to the bone surface, implant surface, and inferior surface of the flap. Closure is accomplished with 5.0 Monocryl suture and a bioactive wound dressing created by additional application of PRP and PPP over the surgical site before dismissal. After 3 months, the removal of the temporary allows not only for the final torquing of the stock abutment to 30 Ncm, but also for inspection of the sulcular environment and emergence profile created (Figure 5F).

Figure 5G illustrates the final implant-supported restoration and AGC® (Aesthetic Galvanotechnik Crown)<sup>g</sup>, which was seated 4 months after the initial surgical appointment. Note the excellent soft tissue maturity level, interproximal contours, and emergence profile that have been formed and maintained throughout the healing phase. The case

complete final periapical radiograph is shown in Figure 5H. Note how the bone contours created by the sculpted implant receptacle site have been maintained in the final radiograph and a stable sulcular/biologic width environment bony interface has been established.

### Case 2—Multiple Tooth Replacement

A 56-year-old man (nonsmoker) presented for implant reconstruction of the mandibular left posterior sextant at teeth Nos. 19 and 20 (Figure 6A). After maxillary and mandibular study models are obtained, and mounted on a KaVo Protar articulator<sup>h</sup>, the fabrication of the TempStent™ surgical guide/provisional system is completed, and the appropriate sites for implant position cored. After administering an appropriate local anesthetic and crestal incision, followed by full-thickness mucoperiosteal flap elevation, the surgeon creates the sculpted implant receptacle site, preceding reinsertion of the surgical guide (Figure 6B). Observe how creation of the proposed osseous contour (sculpted implant receptacle site) for the final restoration follows the contours of the surgical guide.

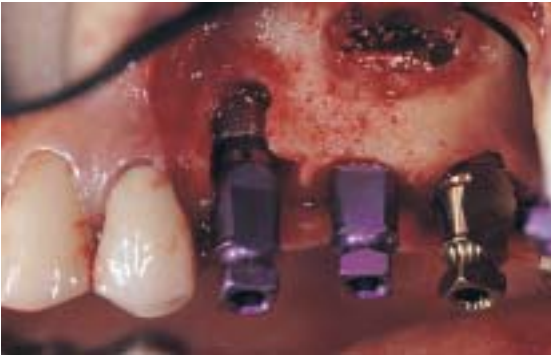<sup>f</sup>Centerpulse, Carlsbad, CA 92008-7308; (760) 929-4300

<sup>g</sup>CeraMed, Lakewood, CO 80228; (800) 426-7836

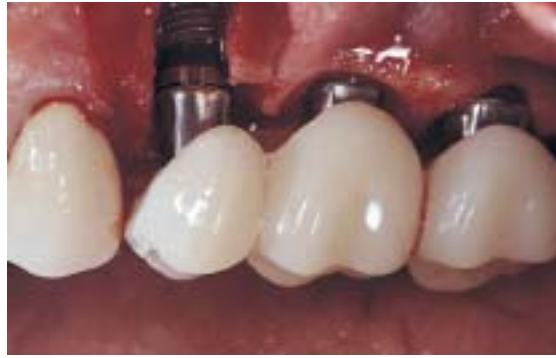<sup>h</sup>Wieland Dental Systems, Milford, CT 06460; (866) 876-0885

<sup>i</sup>KaVo USA, Lake Zurich, IL 60047; (800) 323-8029





**Figure 7C**—Implant placement in conjunction with sinus elevation surgery.



**Figure 7D**—Abutments seated and conversion of the TempStent™ into the provisional restoration.

After atraumatic coring procedures, and application of PRP in the osteotomy sites, placement of the implants is accomplished. Two Paragon Tapered Screw Vents<sup>®</sup> are placed: a 5.7-mm diameter, 13-mm length implant at the No. 19 position, and a 4.7-mm diameter, 13-mm length implant at the No. 20 position. The creation of the sculpted implant receptacle site eliminates the countersinking procedure, and allows the implant collar to remain above the crest of the bone, but within the environment of the interdental bone height (Figure 6C). After preparing and polishing two HLA abutments<sup>®</sup>, a 4/5 and 5/6 at the appropriate implant sites, placement of the abutments (Figure 6C) precedes retrofitting and marginal adaptation of the provisional restorations. Closure is accomplished with 4.0 Vicryl Rapide suture in a continuous sling/horizontal mattress suturing technique (Figure 6D). Evaluation of the patient's occlusion confirms no occlusal contact in centric relation or lateral excursive movements.

After observation for 2 months, a fracture is detected at tooth No. 18, and a third immediate restored implant is placed in the mandibular left posterior sextant. Figure 6E shows the case complete clinical appearance of the three immediate restored implants at 4 months after surgery. Figure 6F shows the case complete panoramic radiograph of the mandibular left posterior sextant.

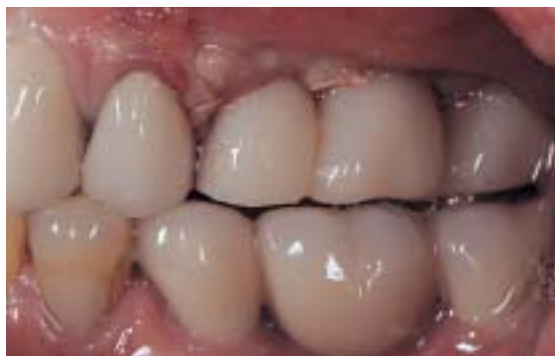### Case 3—Multiple Tooth Replacement with Sinus Elevation

A 63-year-old woman (nonsmoker) presented for treatment of a vertical fracture at tooth No. 13 (Figure 7A). The preoperative panoramic radiograph is shown in Figure 7B.

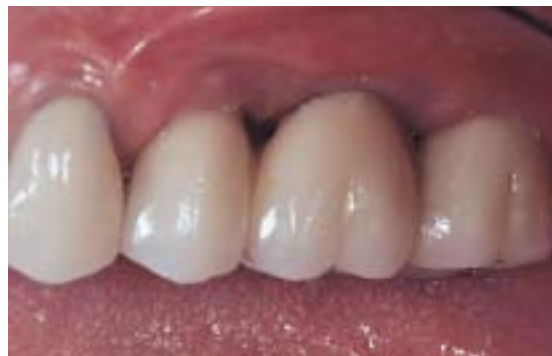After the pretreatment diagnostic and planning phase previously mentioned is completed, TempStent™ is fabricated not only to provide surgical guidance, but also to serve as the provisional restoration. Because of the pneumatized maxillary left sinus, sinus elevation surgery is added to the treatment plan, in addition to placement of the three implants.

After administering an appropriate local anesthetic, a sulcular incision is made at the buccal and palatal of teeth Nos. 13 and 15, crestally at No. 14, with two vertical releasing incisions at the distal of No. 12 and distal line angle of No. 15. After full-thickness mucoperiosteal flap elevation, the creation of an osteotomy in the lateral wall of the maxillae, just inferior to the zygomatic arch, allows for access to, and elevation of, the lateral wall of the maxillae. Attached to the Schneiderian membrane, the lateral wall and the inferior portion of the sinus membrane itself are rotated medially and superiorly to create the receptacle for the sinus graft. Insertion of the surgical guide allows for preparation of the implant sites at the Nos. 13, 14, and 15 areas.

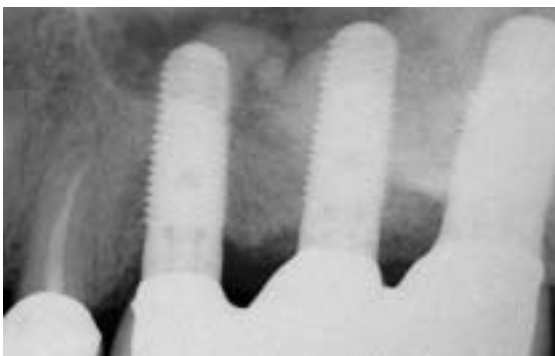Before implant placement, PRP is applied to the sinus cavity via the access opening, and the graft complex (PRP and PepGen P-15™) is placed anteriorly, medially, and distally in the sinus. This technique ensures that grafting material is present at the aforementioned areas of the sinus before placement of the implants. Additional application of PRP in the sinus precedes implant placement. Three Paragon Tapered Screw Vent implants are placed: a 5.7-mm diameter, 13-mm length at the No. 15 site, followed by two 4.7-mm diameter 13-mm in length implants at the Nos. 13 and 14 sites, respectively (Figure 7C). After removal of the



**Figure 7E**—Closure and left lateral centric occlusion view.



**Figure 7F**—Case complete clinical view of the immediate restored implants placed in conjunction with sinus elevation surgery at 5½ months.



**Figure 7G**—Case complete periapical radiograph.

implant carriers, the preprepared HLA stock abutments are seated, and the provisional restoration is inserted to confirm implant placement, before retrofitting with a composite material (Figure 7D). After the conversion of the surgical guide to the provisional restoration, cementation of the restoration is achieved with a strong temporary cement. Application of PRP over the lateral aspect of the maxillae precedes additional grafting with the PRP/PepGen™ graft complex at the osteotomy site in the lateral wall of the maxillae, and the peri-implant defect sites. Closure is accomplished with 4.0 Vicryl Rapide sutures (Figure 7E). Note that in centric occlusion, disclusion is present from Nos. 13 to 15. In the normal chewing cycle, small amounts of load will undoubtedly be present, and the author observes that enhancement of the maturation phase of the graft occurs, based on earlier definitive load times.

After careful observation for 4½ months, the patient is referred for completion of implant prosthetics. The final implant-supported restorations (Figure 7F) are seated 5½ months after the initial, and only, surgical procedure. The case complete periapical radiograph shows the sinus graft well incorporated at the level of the implants (Figure 7G).

## Conclusion

Implant treatment has previously been separated into the surgical and restorative phases. Depending on the complexity of the planned site, the surgical phase may require two to four procedures in conventional implant treatment. The restorative phase, especially in the esthetic zone, may require tissue sculpting and provisionalization to achieve the foundation not only for esthetics, but also for long-term restorative success. Over the years, conventional implant treatment has proven to be a highly successful treatment option for replacing the natural tooth system.

Advancements in surgical techniques, bone grafting materials, and bioengineering of the surgical site, have allowed the implant surgeon to decrease treatment times and possibly surgical visits. However, without proper communication among the surgeon, restorative dentist, and laboratory technician, poor or improper treatment planning leads to complex, and/or compromised prosthetic procedures. Continued advancements in surgical stent designs and the incorporation of provisional restorations during implant placement have allowed the implant team (ie, surgeon, reconstructive dentist, and laboratory technician) to better communicate the parameters for the functional, biological, and esthetic success in implant restorations.

The immediate restoration of dental implants is an exciting option the implant team can offer patients seeking implant treatment. The incorporation of a provisional restoration during implant placement provides the patient with a stable, esthetic temporary restoration. From a periodontal perspective, the author observes that the preservation of

interdental bone, creation or maintenance of the soft tissue, and formation of a sound biologic width environment are all benefits of immediate restoration—in addition to decreasing patient treatment time. The author recommends continued research and clinical studies on this procedure to supplement initial clinical reports presented in recent literature.

## Disclosure

The author of this article works as a consultant for Centerpulse, Dentsply Friadent CeraMed, and Harvest Technologies Corporation.

## References

1. Wohrle PS. Single-tooth replacement in the aesthetic zone with immediate provisionalization: fourteen consecutive case reports. *Pract Periodontics Aesthet Dent*. 1998;10:1107-1114.
2. Salama H, Salama MA, Garber D, et al. The interproximal height of bone: the guidepost to predictable aesthetic strategies and soft tissue contours in anterior tooth replacement. *Pract Periodontics Aesthet Dent*. 1998;10:1131-1141.
3. Saadoun AP, Le Gall MG. Periodontal implications in implant treatment planning for aesthetic results. *Pract Periodontics Aesthet Dent*. 1998;10:655-664.
4. Kois JC. Altering gingival levels: the restorative connections. Part 1: biological variables. *J Esthet Dent*. 1994;6:3-9.
5. Tarnow DP, Magne AW, Fletcher P. The effect from the distance from the contact point to the crest of one on the presence or absence of interproximal dental papillae. *J Periodontol*. 1992;63:995-996.
6. Tarnow DP, Cho SC, Wallace SS. The effect of inter-implant distance on the height of the inter-implant bone crest. *J Periodontol*. 2000;71:546-549.
7. Salama H, Salama M. The role of orthodontic extrusive remodeling in the enhancement of soft and hard tissue profiles prior to implant placement: a systematic approach to the management of extraction site defects. *Int J Periodontics Restorative Dent*. 1993;13:312-333.
8. Kan JY, Rungcharassaeng K. Immediate placement and provisionalization of maxillary anterior single implants: a surgical and prosthetic rationale. *Pract Periodontics Aesthet Dent*. 2000;12:817-824.
9. Saadoun AP. Immediate implant placement and temporization in extraction and healing sites. *Compend Contin Educ Dent*. 2002;23:309-323.
10. Marx RE, Carlson ER, Eichstaedt RM, et al. Platelet rich plasma. Growth factor enhancement for bone grafts. *Oral Surg Oral Med Oral Pathol Radiol Endod*. 1998;85:638-646.
11. Lynch SE, Genco RJ, Marx RE, (eds). *Tissue Engineering: Applications in Maxillofacial Surgery and Periodontics*. Carol Stream, IL: Quintessence Publishing Co, 71-77, 1999.
12. Petrunaro PS. Immediate restoration of dental implants after tooth removal: A new technique to provide esthetic replacement of the natural tooth system. *International Magazine of Oral Implantol*. 2001;2:6-16.
13. Petrunaro PS. Immediate restoration of multiple tooth implants for aesthetic implant restorations. *Implant Dent*. 2002;11:118-126.
14. Petrunaro PS, Maragos C, Matheson O. Using the Master Diagnostic Model® to enhance restorative success in implant treatment. *Compend Contin Educ Dent*. 2000;21:33-42.
15. Petrunaro PS. Using the TempStent™ technique to simplify surgical stent and esthetic temporary fabrication in immediately restored implants in the esthetic zone. *Contemporary Esthetics and Restorative Practice*. 2002;6(5):84-90.
16. Jensen J, Sindet-Pedersen S. Autogenous mandibular bone grafts and osseointegrated implants for reconstruction of the severely atrophied maxilla: a preliminary report. *J Oral Maxillofac Surg*. 1991;49:1277-1287.
17. Misch CM, Misch CE, Resnik RR, et al. Reconstruction of maxillary alveolar defects with mandibular symphysis grafts for dental implants: a preliminary procedural report. *Int J Oral Maxillofac Implants*. 1992;7:360-366.
18. Jensen J, Sinder-Pedersen S, Oliver AJ. Varying treatment strategies for reconstruction of maxillary atrophy with implants: results in 98 patients. *J Oral Maxillofac Surg*. 1994;52:210-216.
19. Misch CM, Misch CE. The repair of localized severe ridge defects for implant placement using mandibular bone grafts. *Implant Dent*. 1995;4:261-267.
20. Krauser JT, Rohrer MD, Wallace SS. Human histologic and histomorphometric analysis comparing OsteoGraf/N with Pep-Gen P-15 in the maxillary sinus elevation procedure: A case report. *Implant Dent*. 2000;9:298-302.
21. Smiler DG. Comparison of anorganic bovine material with and without synthetic peptide in a sinus elevation: A case study. *Implant Dent*. 2001;10(2):139-142.
22. Mellonig JT, Bowers GM, Bailey RC. Comparison of bone graft materials Part 1. New bone formation with autografts and allografts determined by Strontium-85. *J Periodontol*. 1981;52:291-296.
23. Jarcho M. Calcium phosphates as hard tissue prosthetics. *Clin Orthop*. 1981;157:259-278.
24. Froum SJ. Human histologic evaluation of HTR polymer and freeze-dried bone allograft. *J Clin Periodontol*. 1996;23:615-620.
25. Shapoff CA, Alexander DC, Clark AE. Clinical use of bioactive glass particulate in the treatment of human osseous defects. *Compend Contin Educ Dent*. 1997;18:352-358.
26. Sottasanti JS. Calcium sulfate: a biodegradable and biocompatible barrier for guided tissue regeneration. *Compend Contin Educ Dent*. 1992;13:226-234.
27. Sottasanti JS. Aesthetic extractions with calcium sulfate and the principles of guided tissue regeneration. *Pract Periodontics Aesthet Dent*. 1993;5:61-69.
28. Urist MR, Strates BS. Bone morphogenic protein. *J Dent Res*. 1971;50:1392-1406.
29. Urist MR, Silverman BF, Buring K, et al. The bone induction principle. *Clin Orthop*. 1967;53:243-283.
30. Burwell RG. The function of bone marrow in the incorporation of a bone graft. *Clin Orthop*. 1985;200:125-141.
31. Callan DP, Rohrer MD. Use of bovine-derived hydroxyapatite in the treatment of edentulous ridge defects: a human clinical and histologic case report. *J Periodontol*. 1993;64:575-582.
32. Petrunaro PS. Platelet-rich plasma for dental implants and soft-tissue grafting. *Dent Implantol Update*. 2001;12:41-46.
33. Petrunaro PS. Using platelet-rich plasma to accelerate soft tissue maturation in esthetic periodontal surgery. *Compend Contin Educ Dent*. 2001;22:729-746.
34. Petrunaro PS. Immediate restoration of dental implants in the aesthetic zone. *Dent Implantol Update*. 2001;12:89-95.
35. Marx RE, Garg AK. Bone graft physiology with use of PRP and hyperbaric oxygen. In: Jensen OT. *The Sinus Bone Grafts*, Chicago, IL, Quintessence Publishing Co, 1999.
36. Anitua E. Plasma rich in growth factors: preliminary results of use in the preparation of future sites for implants. *Int J Oral Maxillofac Implants*. 1999;14:529-535.

# Quiz 1

1. Administration of which antibiotic is recommended the day before surgery?
  - a. tetracycline
  - b. Augmentin®
  - c. erythromycin
  - d. cephalosporin
2. In sinus elevation cases, whether using the lateral wall osteotomy approach, or the osteotome technique, the surgeon must also be sure to preserve the:
  - a. buccal plate.
  - b. lingual plate.
  - c. Schneiderian membrane.
  - d. Tetralogy of Fallot.
3. Removal of what is absolutely essential so as to provide the existence of a bone/implant interface?
  - a. gingival epithelium
  - b. gingival sulcus
  - c. buccal epithelium
  - d. granulomatous tissue
4. The implant of choice for this technique should be:
  - a. one with a thread design that is self-tapping in nature.
  - b. one that is tapered.
  - c. one with a roughened surface.
  - d. all of the above
5. The polished implant collar should be:
  - a.  $\leq 1$  mm in height.
  - b.  $\leq 2$  mm in height.
  - c.  $\leq 3$  mm in height.
  - d.  $\leq 4$  mm in height.
6. According to the author's clinical experience, which bone is the best grafting material available?
  - a. allogenic
  - b. autogenous
  - c. alloplastic
  - d. xenographic
7. The ideal autogenous vehicle to reconstitute the alloplastic, allogenic, or xenographic substrate is:
  - a. PRP.
  - b. saline.
  - c. concentrated saliva.
  - d. reconstituted saliva.
8. The incorporation of the temporary/surgical guide system, which the author uses, allows for the preparation of the stock abutment to be accomplished:
  - a. during implant insertion.
  - b. after implant insertion.
  - c. in advance.
  - d. implant preparation is never required.
9. The prescribed healing phase is how long in sinus grafted cases?
  - a. 1 month
  - b. 2 months
  - c. 3 months
  - d. 4 to 5 months
10. If the restorative clinician will use the stock abutment seated at the initial visit, the abutment is torqued to:
  - a. 10 Ncm.
  - b. 20 Ncm.
  - c. 30 Ncm.
  - d. 40 Ncm.

This article provides 1 hour of CE credit from Dental Learning Systems, in association with the University of Southern California School of Dentistry and the University of Pennsylvania School of Dental Medicine, representatives of which have reviewed the articles in this issue for acceptance. Record your answers on the enclosed answer sheet or submit them on a separate sheet of paper. You may also phone your answers in to (888) 596-4605 or fax them to (703) 404-1801. Be sure to include your name, address, telephone number, and social security number.